

# Traumatic lesions in human osteological remains from Neolithic Lithuania

**RIMANTAS JANKAUSKAS**


The Neolithic period in Lithuania is represented by several cultures: the Early Neolithic Nemunas-Narva Ceramic culture, the Late Neolithic Corded Pottery culture, and, a hybrid of the first two cultures, the Pamarių Baltic Coastal culture of the Late Neolithic (also known as the Rzucewo culture in northern Poland). An extensive discussion of the archaeology of these cultures is provided by Rimantienė (1984), Girininkas (1985), Butrimas (1985), and Butrimas and Kazakevičius (1985), while paleoanthropological analyses of skeletal remains are described by Česnys (1985a, 1985b, 1985c, 1991a, 1991b, 1991c). This paper is restricted to a discussion of one type of paleopathology that appears within the populations of all three of these Neolithic cultures — traumatic lesions.

The Neolithic sample of human osteological remains examined in this study consisted of 19 individuals (eight males, seven females and four sub-adults). Seven of them are from the Early Neolithic Nemunas-Narva culture (the individuals from Turlojiškė and Kretuonas), three from the Corded Pottery culture (Plinkaigalis), and the remaining nine are from the Late Neolithic Pamarių culture (Duonkalnis and Spiginas). The results of the paleopathological analyses, which included both macroscopic and roentgenographic investigation of these specimens, are presented in order of archaeological age.


## Results and Discussion

The “Turlojiškė man” (a male of 25-30 years) is represented by a nearly complete and well preserved skeleton. Three impressed fractures on his skull vault (Fig. 1) are evident:

a) Elliptic impression (45 x 2mm) on the frontal bone near bregma, crossing the coronal suture and extending into the right parietal (Fig. 2). Its center has a shallow groove of 36mm in length and 4mm in width. The impression has uneven sharp edges with open diploë without signs of regeneration. The defect on the internal plate is greater than that on the external. The internal surface of frontal bone has a forwardly directed fracture line.



**Fig. 1.** General view of the "Turlojiškė man" skull vault. Note traces of impressed fractures.  
**1 pav.** Bendras Turlojiškės žmogaus kaukolės skliauto vaizdas. Matomi impresiniai lūžimai.



**Fig. 2.** Elliptic impression near bregma crossing the right coronal suture on the "Turlojiškė man" skull vault.

**2 pav.** Turlojiškės žmogaus kaukolės skliautas. Elipsės formos impresinis lūžimas prie bregmos, kertantis vainikinę siūlę.

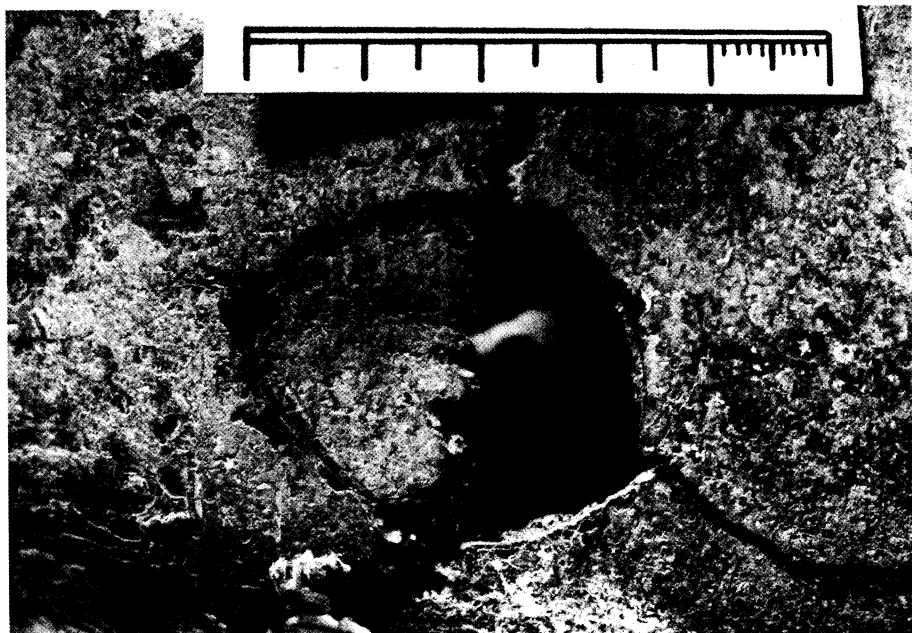

Fig. 3. Oval impression on the left coronal suture on the "Turlojiškė man" skull vault.

3 pav. Turlojiškės žmogaus kaukolės skliautas. Ovalus impresinis lūžimas kairėje vainikinės siūlės pusėje.



Fig. 4. Elongated defect (impressed fracture) on the left *tuber parietale* of the "Turlojiškė man" skull vault.

4 pav. Turlojiškės žmogaus kaukolės skliautas. Pailgas defektas (impresinis lūžimas) ant kairiojo momens gumburo.

b) Oval impression measuring 35 x 30mm on the left coronal suture, 14mm from the *linea temporalis superior* (Fig. 3). Edges are sharp and uneven, diploë open. Internal diameter exceeds external, and the fracture line on the internal plate is directed forwardly.

c) Elongated defect (28 x 9mm) on the left *tuber parietale* with sharp uneven edges and open diploë (Fig. 4). All impressions are connected by fracture lines (see Fig. 1). Character of the lesions allows us to suggest that all of these impressions were left by a blunt, hard instrument(s), and that these blows could have been the cause of death. In addition, the "Turlojiškė man" had rare anomalies on his vertebral column, which will be discussed later.

The Early Neolithic sample from Kretuonas (excavated by A. Girininkas) consists of six skeletons in various state of preservation. The only individual to display lesions of probable traumatic origin was a male, 50-55 years of age. He was represented by a nearly complete skeleton. The skull vault had eight small shallow impressions of varying shapes on both parietals. Their rounded margins and bottoms were covered by compact bone. It is probable that they represent healed wounds, originally produced by a blunt weapon.

Individuals of the Corded Pottery culture are represented by three Late Neolithic graves, containing partial skeletons, from the Plinkaigalis burial ground (excavated by V. Kazakevičius). Plinkaigalis Grave 317 contained a well preserved skeleton of a female, 50-55 years old. The left distal tibiofibular articulation bears signs of probable traumatic damage: marked osteophytes in the region of their junction. This could be the result of disruption of ligaments with consequent ossification.

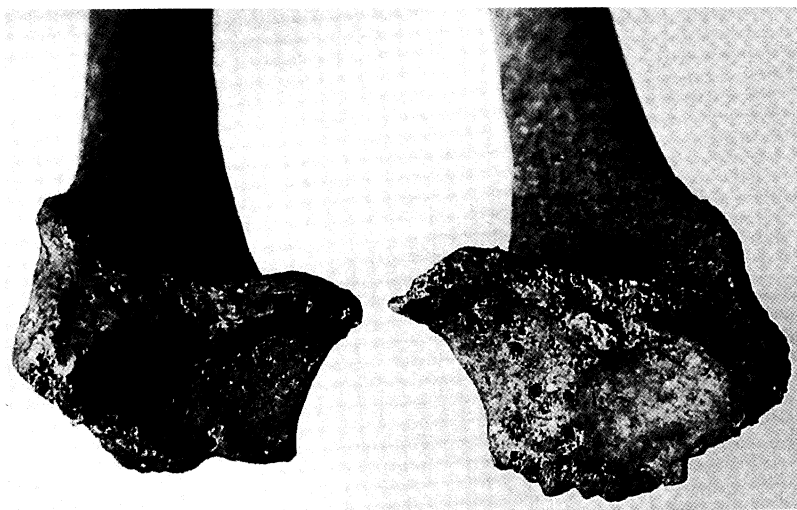
Individuals of the Pamarių culture from Duonkalnis are represented by eight graves, as well as the bones from the disrupted graves of at least six more individuals (the skeletal remains from these disrupted graves did not show any evidence of trauma). One partial skeleton from the Pamarių period at Spiginas was also examined (both sites excavated by A. Butrimas).

Duonkalnis Grave 3 contained a partial skeleton of a female, 25-30 years old, without evidence of pathology, except for a small shallow oval depression (14 x 9mm) on the right parietal bone near the sagittal suture. As the defect margins are rounded and completely obliterated by compact bone, the depression can be interpreted as the consequence of a completely healed blunt injury to the skull vault.


Duonkalnis Grave 4 represents an almost complete skeleton of a mature male (50-55 years in age) with evidence of multiple pathological changes. The occipital bone and parts of both parietals exhibited an area of periostitis (about 9cm wide and not less than 11cm in length) with clear margins (Fig. 5). The internal skull vault surface is without pathology. Such superficial periostitis could be caused by infection after local scalp trauma. Similar lesions after scalping are known in North America Indian populations (Steinbock 1976). There is also evidence of scalping practices in the Old World (Ortner and Putschar 1985). For example, unhealed traces of scalping are described on a Middle Neolithic skull from Alvastra, Sweden (During and Nilsson 1991). The hypothesis, therefore, that similar changes on the Duonkalnis Grave 4 skull represent a healed scalping, deserves consideration.



**Fig. 5.** Localized periostitis area on the skull from Duonkalnis Grave 4.  
**5 pav.** Lokalizuoto periostito sritis ant Duonkalnio 4 kapo kaukolės skliauto.

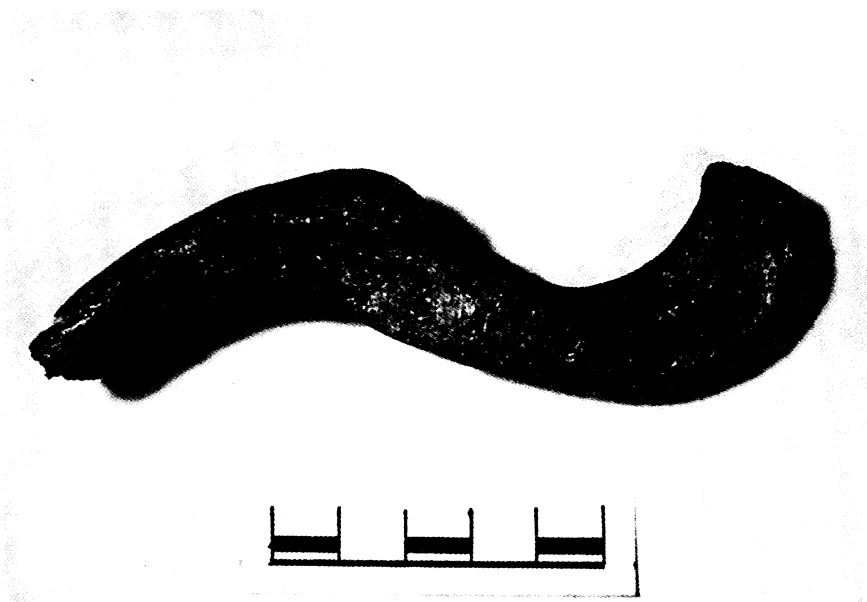

**Fig. 6.** Arthrotic changes on the distal radii from Duonkalnis Grave 4. Note severe lesions (pitting and eburnation) of the left radius (right side of photo).  
**6 pav.** Duonkalnis 4 kapas. Artrotiniai pakitimai ant stipinkaulių stipininių riešo sąnarių paviršių. Matomi ryškūs kairiojo stipinkaulio pakitimai (akytumas ir sąnariinių paviršių nusišlifavimas) (dešinėje nuotr. pusėje).



**Fig. 7.** Healed "parry fracture" of the left ulna diaphysis from Duonkalnis Grave 6. (bottom of photo).

**7 pav.** Duonkalnis, 6 kapas. Sugijęs kairiojo alkūnkaulio diafizės „gynimosi” lūžimas (nuotr. apačioje).



**Fig. 8.** Well healed fracture of the right clavicle from Duonkalnis Grave 7.

**8 pav.** Duonkalnis, 7 kapas. Gerai sugijęs dešiniojo raktikaulio lūžimas.

Asymmetric arthrotic changes of both wrist joints also are of interest (Fig. 6). The left radius has marked changes on the ulnar side of its carpal articular surface. The right radius bears only slight osteophytes. Although the left ulna's distal end is missing *post mortem*, the roentgenograms show bone marrow obliteration and other signs of healing. Such changes suggest traumatic arthritis as a preferable explanation of the left wrist joint lesion. Evidently, this is a case of "parry fracture" — a trauma to the forearm, usually the ulna, received when an individual raises his hands to protect his head from a blow.

Duonkalnis Grave 6 is an incomplete skeleton of a female, 35-40 years old. She has evidence of a healed "parry fracture" on her left ulna (Fig. 7).

Duonkalnis Grave 7 contained a partial skeleton of a mature male. His right clavicle exhibited signs of a healed fracture (Fig. 8). The remaining skeleton was without pathological lesions.

Spiginas Grave 2 contained a very fragmentary skeleton of a male, 50-55 years old, without any evident pathology.

## Conclusions

The fragmentary nature and small size of this Neolithic skeletal sample from Lithuania limits our ability to draw broad conclusions. Nonetheless, the high incidence of traumatic lesions may be significant. Four skull vaults (28.6% of the sample) bear signs of traumatic lesions. Also noted were one healed fracture of the right clavicle (7.1%) and two healed "parry fractures" of the left ulnas (10.5%). Several cases of severe osteoarthritis suggest debilitating physical activities or occupations.

In conclusion, paleopathologies of the Neolithic population in Lithuania reveal strikingly high levels of traumatism, especially related to violence, and enormous physical stresses in adult individuals. Future comparison of human osteological material from other Neolithic sites in the peri-Baltic would be useful to verify and expand upon our findings.

**Acknowledgement.** All of the photos are the work of K. Vainoras.

## References

- Butrimas, A. and V. Kazakevičius (1985) "Ankstyvieji virvelinės keramikos kultūros kapai Lietuvoje: Archeologiniai tyrimai." *Lietuvos archeologija* 4: 14-19.
- Butrimas, A. (1985) "Duonkalnis: vėlyvojo neolito gyvenvietė, alkas ir kapinynas. Archeologiniai tyrimai." *Lietuvos archeologija* 4: 30-49.
- Česnys, G. (1985a) "Kretuono 1-os gyvenvietės vidurinio neolito kapai: Antropologiniai tyrimai." *Lietuvos archeologija* 4: 9-12.
- Česnys, G. (1985b) "Ankstyvieji virvelinės keramikos kultūros kapai Lietuvoje: Antropologiniai tyrimai." *Lietuvos archeologija* 4: 19-22.
- Česnys, G. (1985c) "Duonkalnis: vėlyvojo neolito gyvenvietė, alkas ir kapinynas. Antropologiniai tyrimai." *Lietuvos archeologija* 4: 49-56.
- Česnys, G. (1991a) "The Neolithic and Bronze Age man in the South-East Baltic area. 1. An inventory of recent and old craniological materials from a univariate view point." *Homo* 42 (1): 1-20.

- Česnys, G. (1991b) "The Neolithic and Bronze Age man in the South-East Baltic area: 2. Multivariate approach." *Homo* 42 (2): 130-149.
- Česnys, G. (1991c) "The Neolithic and Bronze Age man in the South-East Baltic area: 3. An essay on the genesis of craniological types." *Homo* 42 (2): 242-243.
- During, E. M. and L. Nilsson (1991). "Mechanical surface analysis of bone: a case study of cut marks and enamel hypoplasia on a Neolithic cranium from Sweden." *American Journal of Physical Anthropology* 84 (2): 113-125.
- Girininkas, A. (1985) "Kretuono 1-os gyvenvietės vidurinio neolito kapai: Archeologiniai tyrimai." *Lietuvos archeologija* 4: 5-9.
- Ortner, D. J. and W. G. J. Putschar (1985) *Identification of Pathological Conditions in Human Skeletal Remains*. Washington: Smithsonian Institution Press.
- Rimantienė, R. (1984) *Akmens amžius Lietuvoje*. Vilnius: Mokslas.
- Steinbock, R. T. (1976) *Paleopathological diagnosis and interpretation*. Springfield, IL: C.C. Thomas.

## Traumų pėdsakai Lietuvos neolito osteologinėje medžiagoje

**RIMANTAS JANKAUSKAS**

### *Santrauka*

Ištirta 19 asmenų (8 vyrų, 7 moterų ir 4 vaikų bei paauglių) palaikai. Keturi kaukolių skliautai (iš 14) turėjo traumų pėdsakus (28.6%): dviejuose buvo rasti nedideli sugiję impresiniai lūžimai; vienu atveju — lokalizuoto periosito aiškiomis ribomis pėdsakai viršugalvyje (sugijusio skalpavimo žymė?); kitu atveju — 3 nesugiję impresiniai lūžimai nuo smūgių kietu buku daiktu (tikėtina šio vyro mirties priežastis). Taip pat rasta 1 sugijęs dešiniojo raktikaulio lūžimas (7,1%) ir du sugiję kairiųjų alkūnkaulių „gynimosi“ lūžimai (10,5%). Toks didelis traumų dažnumas greičiausia atspindi sunkių to meto gyvenimo sąlygų ypatybes.